

A Decapod Hemocyte Classification Scheme Integrating Morphology, Cytochemistry, and Function

JO ELLEN HOSE, GARY G. MARTIN, AND ALISON SUE GERARD

Department of Biology, Occidental College, Los Angeles, California 90041

Abstract. We have examined the hemocytes of three decapod crustaceans (*Homarus americanus*, *Panulirus interruptus*, and *Loxorhynchus grandis*) and propose a classification of these cells based on morphology, cytochemistry, and studies of cell functions. In all species, hyaline cells and granulocytes were identified. Although we have retained the widely used names for these cells, we show that traditional morphological features alone do not accurately differentiate between these categories. Historically, the term hyaline cell refers to hemocytes that contain no or only a few cytoplasmic granules, whereas granulocytes contain abundant granules. However, the size and number of granules in hyaline cells vary greatly between species and therefore are not useful criteria for identifying these cells. Since morphological identification alone is inadequate and misleading, especially with regard to hyaline cells, a combination of morphological, cytochemical and functional methods is necessary to identify decapod hemocytes. Features of hyaline cells include: a higher nucleocytoplasmic ratio than that of granulocytes, the presence of abundant small (~50 nm), round, electron-dense deposits in the cytoplasm, and their accumulation of trypan blue dye prior to cytolysis. Granulocytes do not take up trypan blue or lyse during a 5-min incubation, and they contain prophenoloxidase and hydrolases. Hyaline cells are involved in the initiation of hemolymph coagulation whereas granulocytes are involved in defense against foreign material by phagocytosis and encapsulation. We propose that these criteria be applied to other crustacean species and expect that they will facilitate our understanding of the physiological roles of their hemocytes.

Introduction

In crustaceans, circulating hemocytes are thought to be involved in hardening of the exoskeleton, prevention

of blood loss and the confinement of invasive organisms by clot formation, recognition of non-self, phagocytosis, and encapsulation (Bauchau, 1981; Ratner and Vinson, 1983). Although recent research has expanded the various physiological roles played by crustacean hemocytes, extension of this information from one species to another is difficult because of the lack of a unified classification scheme for the hemocytes of all crustacea. Prior hemocyte classification systems rely on tinctorial properties of the cells, which are often subtle or subjective, and seldom apply to other species (Martin and Graves, 1985).

Using the penaeid shrimp *Sicyonia ingentis* as a prototype for decapod crustaceans, a hemocyte classification system was developed, which relates cellular morphology at the light and electron microscope levels, cytochemistry, and three essential functions: clotting, phagocytosis, and encapsulation (Martin *et al.*, 1987; Hose *et al.*, 1987; Omori *et al.*, 1989; Hose and Martin, 1989). The choice of this species proved serendipitous because the three types of hemocytes are morphologically distinct and clotting occurs by explosive cytolysis (Tait's type C coagulation; Tait, 1911), making identification of the clotting cell type relatively easy. At the electron microscope level, the cells that initiate clotting are readily identified by several features typical of hyaline cells (small size, a high nucleocytoplasmic ratio, and scarcity of cytoplasmic granules) and by the presence of numerous, small (~50 nm diameter), electron-dense deposits in the cytoplasm. In addition, the hyaline cells selectively stain with Sudan black B, as does coagulogen extracted from cell-free hemolymph of *Panulirus interruptus* and *Astacus leptodactylus* (Durliat, 1985). During lysis of these cells, the deposits appear to extend through breaks in the plasma membrane and hydrate to produce the clot (Omori *et al.*, 1989). The granulocytes are larger cells with a lower nucleocytoplasmic ratio and contain numerous small (0.4 μm diam.) or large (0.8 μm diam.) granules. Granulocytes (small and large granule hemocytes) show no

morphological changes during coagulation and are capable of phagocytosis of bacteria and encapsulation of fungal hyphae. Phagocytosis is accomplished primarily by small granule hemocytes (Hose and Martin, 1989); they contain many vesicles and occasional granules that stain for acid hydrolases (acid phosphatase, β -glucuronidase, and nonspecific esterase) (Hose *et al.*, 1987). Encapsulation is initiated by large granule hemocytes and, to a lesser extent, by small granule hemocytes (Hose and Martin, 1989). Prophenoloxidase (PPO), an enzyme involved with melanization of encapsulated material and possibly the recognition of non-self items (Söderhäll, 1982), is most abundant in large granule hemocytes and to a lesser degree in some small granule cells. In contrast, hyaline cells, which do not phagocytize bacteria or assist in capsule formation, do not contain PPO and only rarely acid phosphatase (Hose *et al.*, 1987). Thus the division of shrimp hemocytes into two functional groups, hyaline (or clotting) cells and granulocytes, is supported by morphology, cytochemistry, and function.

This paper extends the results of the shrimp studies to other decapods and attempts to develop a unified hemocyte classification system for the diverse assemblage of crustaceans. This diversity is exemplified by the existence of multiple coagulation mechanisms. In contrast to clotting via explosive cytolysis as in the shrimp (type C according to Tait, 1911), other decapods exhibit type-A coagulation which is distinguished by the formation of a dense hemocyte network which seals off the injury and plasma coagulation is not apparent or type-B coagulation in which hemocyte aggregation is followed by plasma coagulation (Tait, 1911). In the present study, we examined the hemocytes in one species with type-A coagulation (a crab, *Loxorhynchus grandis*), one species with type-B coagulation (the Maine lobster, *Homarus americanus*), and one species with type-C coagulation (the spiny lobster, *Panulirus interruptus*). Light and electron microscopic features of hemocytes from these three decapods are compared to those identified in the shrimp and correlated with a suite of cytochemical characteristics (Sudan black B, acid phosphatase, and PPO) and a group of essential physiological functions (clotting, phagocytosis, and encapsulation). The methods presented here should facilitate study of decapod hemocytes by providing a framework for practical hemocyte classification.

Materials and Methods

Animals

Spiny lobsters (*P. interruptus*) and sheep crabs (*L. grandis*) were collected in less than 10 m of water at King Harbor Marina, Los Angeles, California. Maine lobsters (*H. americanus*) were purchased commercially. Crusta-

ceans were maintained in flow-through aquaria at 18°C and only intermolt animals were studied.

Microscopic examination of hemocytes

Freshly fixed hemocytes were examined by light microscopy (LM) (brightfield and phase contrast optics) to determine cell size, cell shape, granule size, and differential hemocyte counts. An aliquot of hemolymph (usually 0.2 cc) was withdrawn from the ventral sinus or heart into a 1 cc syringe containing 0.4 cc of fixative (2.5% glutaraldehyde in 0.1 M sodium cacodylate pH 7.8 containing 12% glucose).

Excess fixative was added to a second 0.2 cc hemolymph aliquot, and the cells were processed for examination by electron microscopy. The cells were fixed for 2 h at room temperature and pelleted ($10,000 \times g$ for 1.5 min). Following a 10-min wash in 0.1 M sodium cacodylate (pH 7.8) containing 24% sucrose, the cells were post-fixed in 1% OsO₄ in 0.1 M sodium cacodylate for 1 h at room temperature. Each sample was stained en bloc for 1 h with 3% uranyl acetate in 0.1 M sodium acetate, dehydrated in a graded series of ethanol, and infiltrated and embedded in Spurr's (1969) low viscosity plastic. Thin sections (90 nm) were cut on a Porter Blum MT2B ultramicrotome, stained with lead citrate and examined in a Hitachi HU 11A transmission electron microscope (TEM).

Nucleocytoplasmic ratios were determined by dividing the area of the nucleus by the area of the cell. For hyaline and small granule hemocytes, both areas were clearly identified in light micrographs of immediately fixed cells and measured using a digitizing tablet and Sigma-Scan® computer software (Jandel Scientific). Because the nucleus is difficult to visualize in phase contrast images of large granule hemocytes, measurements were made from thick plastic sections. To ensure that cells were sectioned through their greatest axis, only large granule hemocytes showing typical length and width measurements were used. There was no difference in size measurements of fixed cells examined in wet mounts by phase optics and cells embedded in plastic and sectioned.

Identification of cell-type initiating coagulation

Two previously used approaches helped to identify the type of hemocyte initiating coagulation of the hemolymph: (1) visual examination of hemocyte types accumulating trypan blue, an event we have previously shown to be a direct precursor to cytolysis and ensuing clot formation and (2) ultrastructural examination of hemocytes fixed at stages during clot formation (Omori *et al.*, 1989). For the first technique, 0.1 cc of freshly drawn hemolymph was gently mixed on a glass slide with 0.1 cc of a 1.2% solution of trypan blue in seawater. Within 1–2 min, certain hemocytes accumulate the blue color in

both the cytoplasm and nucleus. By 5 min these cells lyse and the cytoplasm is lost, but the blue staining nuclei remain. Individual cells may be identified and observed as they accumulate the dye and lyse. After 5 min, the number of blue stained nuclei and the cells remaining intact and colorless were counted. Six hundred cells were evaluated for each species.

The second method provided ultrastructural information on the type of hemocyte that initiates coagulation as well as changes in these cells during cytolysis. Aliquots of hemolymph (0.1 cc) and seawater (0.1 ml) were mixed for times ranging from 15 s to 5 min and then fixed by the addition of an excess amount of glutaraldehyde fixative and prepared for TEM examination as described above.

Phagocytosis of bacteria by hemocytes

In vitro phagocytosis experiments were performed as described by Hose and Martin (1989). A glass microscope coverslip was placed into each of two sterile plastic Petri dishes and each covered with 20 ml of shrimp culture medium (SCM, Brody and Chang, in press). Approximately 0.3 cc of hemolymph was added over each coverslip, and hemocytes were allowed to settle and attach to the coverslips for 15 min. Approximately 100,000 cells of a Gram-negative marine bacterium (*Cytophaga* sp.: Occidental College Isolate 1) were added to one of the dishes. Cultures were incubated at 12°C for 3 h. Coverslips were fixed in methanol for 5 min and stained with May Grunwald-Giemsa. Differential counts of approximately 200 hemocytes were performed and the numbers of phagocytic cells (hemocytes containing at least 1 bacterium within a vacuole) were recorded. Dead hemocytes were differentiated from viable cells by the presence of nuclear degeneration (karyolysis, pycnosis).

Fungal encapsulation

The method of Hose and Martin (1989) was used to determine the types of hemocyte that attached to fungal hyphae and initiated capsule formation. Approximately 1 ml of hemolymph was added to 12 ml SCM in a 15 ml plastic centrifuge tube. Small cubes (0.5 mm³) of Sabouraud-dextrose agar containing primarily hyphae of *Fusarium solani* (University of Arizona strain 1623C) were added to the tube; the culture was incubated at 12°C. After 1, 2, and 5 min, a cube was removed and washed gently in SCM to remove nonadherent hemocytes. The cell types attached to the fungus were identified using phase contrast microscopy (total of 200 cells for each species).

Hemocyte cytochemistry

Hemolymph (0.2 cc) was withdrawn into 0.2 cc of 12.5% unbuffered citrate anticoagulant (which prevents lysis of hyaline cells), spread on three glass microscope

slides, and allowed to air dry. Constituents of hemocyte granules and cytoplasm were visualized using methods given in Hose *et al.* (1987). Smears were prepared from six individuals of each species. Where possible, 200 cells per slide were evaluated using brightfield microscopy (1000×); each hemocyte was categorized and individual cellular reactions were recorded.

Lipids and lipoproteins were demonstrated using a commercial Sudan Black B kit (Sigma Chemical Co. Kit #380). Glutaraldehyde-fixed hemocytes were processed according to provided directions except that the nuclear counterstain was not used. Cytoplasmic staining was differentiated from staining of granule or plasma membranes and was termed a positive reaction (Hose *et al.*, 1987). Occasionally entire granules were stained by Sudan Black B; these are noted in the results.

Prophenoloxidase (PPO) activity was evaluated in smears fixed in 2.5% glutaraldehyde in 0.1 M phosphate buffer (pH 7.4) for 1 h at 4°C. The smears were rinsed three times in phosphate buffer (15 min each), then incubated in 0.1% L-DOPA in phosphate buffer for 16 h at room temperature. Black staining of the granules was interpreted as a positive reaction (Hose *et al.*, 1987).

Acid phosphatase in glutaraldehyde-fixed hemocytes was visualized using a commercial research kit (Sigma Chemical Co. Kit #386). Naphthol AS-BI phosphate was used as the substrate, yielding a red-violet reaction product (naphthol AS-BI-fast garnet GBC complex). Although the location and abundance of acid phosphatase was species-specific, the rating system previously used for the shrimp (Hose *et al.*, 1987) was acceptable for use with the lobsters. In the shrimp we recognized the following categories: rare (0 to 3 positive foci per cell), few (4 to 10 foci per cell), intermediate (11 to 30 foci per cell), and many (>30 foci per cell). Because *L. grandis* contained more acid phosphatase foci than the shrimp, the rating system was slightly modified for evaluation of crab hemocytes. A distribution of the number of positive foci per cell was constructed and the limit for the "rare" category placed between the groups containing rare and few foci. Thus while the rare category consisted of less than four foci for shrimp and the lobsters, it was enlarged to include less than six foci for the crab. A rare response was interpreted as negative. Remaining limits were identical for all four species. Two hundred cells were evaluated for each test; each hemocyte was identified and individual cellular reactions were recorded.

Results

Description of hemocyte types

Using morphological criteria previously developed for the shrimp (Martin *et al.*, 1987), three basic cell types were observed in each of the decapods studied; one type

Table I

Comparative hemocyte morphology

	Large granule cells	Small granule cells	Hyaline cells
<i>Homarus americanus</i>			
Cell size (length × width)	23.4 ± 2.2 × 12.3 ± 1.3 (11)	20.9 ± 0.6 × 13.9 ± 0.3 (18)	14.1 ± 0.8 × 11.2 ± 0.6 (16)
Granule diameter	1.3 ± 0.1 (30)	0.9 ± 0.1 (30)	0.9 ± 0.1 (30)
Number of granules	72.7 ± 4.6 (30)	27.3 ± 5.6 (30)	13.9 ± 3.0 (30)
Nucleocytoplasmic ratio	20.3 ± 1.8 (10)	27.5 ± 2.4 (10)	40.0 ± 2.5 (13)
<i>Panulirus interruptus</i>			
Cell size (length × width)	22.6 ± 1.3 × 14.1 ± 0.5 (12)	19.7 ± 0.9 × 10.0 ± 0.3 (18)	14.2 ± 0.5 × 10.6 ± 0.2 (18)
Granule diameter	1.4 ± 0.1 (30)	0.8 ± 0.1 (33)	1.2 ± 0.1 (30)
Number of granules	34.0 ± 2.4 (30)	10.8 ± 4.3 (30)	5.6 ± 0.8 (30)
Nucleocytoplasmic ratio	18.3 ± 1.3 (8)	24.6 ± 2.1 (16)	40.2 ± 1.5 (16)
<i>Loxorhynchus grandis</i>			
Cell size (length × width)	20.4 ± 0.5 × 13.7 ± 0.6 (19)	17.9 ± 0.5 × 10.6 ± 0.4 (15)	14.5 ± 1.0 × 9.1 ± 0.3 (12)
Granule diameter	1.4 ± 0.1 (30)	1.0 ± 0.1 (30)	1.0 ± 0.1 (30)
Number of granules	28.0 ± 4.1 (30)	8.0 ± 1.6 (30)	38.3 ± 5.6 (30)
Nucleocytoplasmic ratio	17.5 ± 1.5 (11)	23.5 ± 1.0 (11)	36.0 ± 1.5 (16)

Measurements are mean ± standard error (number of measurements). Cell sizes are presented in length × width. Cell and granule sizes are in μm . Number of granules is the number per sectioned cell. Nucleocytoplasmic ratios are percentages.

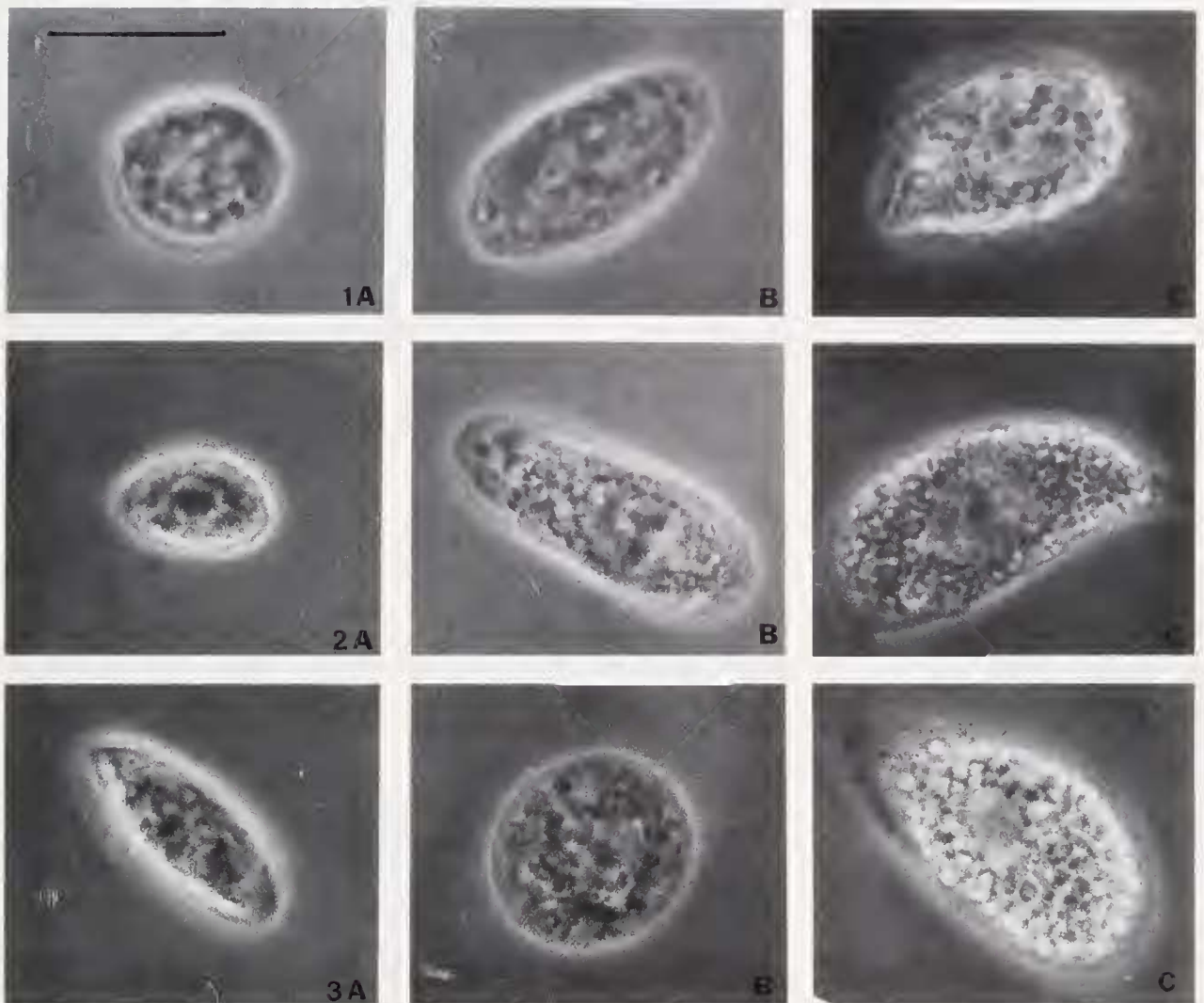
T-tests showed significantly smaller hyaline hemocyte size for all three species compared to either small or large granule hemocytes ($P < 0.05$). Nucleocytoplasmic ratios for hyaline hemocytes of all three species were significantly larger than those of small or large granule hemocytes ($P < 0.05$).

of hyaline cell and two subgroups of granulocytes (small and large granule hemocytes) (Table I).

Hyaline Cells (Figs. 1A–6A). Hyaline cells were the most morphologically diverse type of hemocyte. When examined by phase contrast microscopy, they were generally ovoid in shape, smaller than granulocytes and with a higher nucleocytoplasmic ratio (Table I), and either contained few large granules (*P. interruptus*) or numerous smaller granules (*H. americanus* and *L. grandis*). Most hyaline cells of *H. americanus* measured $21 \times 11 \mu\text{m}$ although smaller hemocytes (from $12 \mu\text{m}$ in the largest dimension) were occasionally observed. The smaller cells may represent immature hyaline cells because they were continuous in size with the hyaline cell and probably correspond to the prohyalocyte category recognized by Cornick and Stewart (1978). Hyaline hemocytes of *H. americanus* had numerous (14/section) small, ovoid granules, $0.9 \mu\text{m}$ long, the contents of which appeared homogeneous and electron dense at the EM level. The cytoplasm contained Golgi bodies, abundant rough endoplasmic reticulum (RER), a circumferential band of microtubules, a few vesicles, mitochondria, and small ($\sim 50 \text{ nm}$ diam.), round, electron-dense deposits (Fig. 7). Hyaline cells of the crab (*L. grandis*) resembled those of the *Homarus*, except they contained more granules (40/section) that, at the EM level, were ovoid, homogeneous, and electron dense. Hyaline hemocytes of the spiny lobster (*P. interruptus*) were distinctive in that only a few (6/section) large ($1.2 \mu\text{m}$ diam.) granules were present. Ultrastructurally the granules had a punctate pattern.

Otherwise, features of the cytoplasm were similar to those described for the other species.

Granulocytes. Granulocytes could be easily differentiated into two groups using phase contrast microscopy: small (Figs. 1B–6B) and large (Figs. 1C–6C) granule hemocytes. Small granule hemocytes contained few to many, round, dark, small (usually $\leq 1.0 \mu\text{m}$ diam.) granules and a relatively small, centrally located nucleus, whereas the cytoplasm of large granule hemocytes was packed with larger ($1.3\text{--}2.0 \mu\text{m}$ diameter), refractile granules that obscured the eccentrically placed nucleus (Table I). However, it was sometimes difficult using TEM to distinguish between small granule hemocytes containing numerous granules and large granule hemocytes because the sectioned granules appeared similar in size. These cells may be part of a single line of maturation in which the number and size of granules in small granule hemocytes increase until the cell is recognized as a large granule hemocyte. To distinguish between small and large granule hemocytes, we relied on (1) the location of the nucleus (centrally or eccentrically placed) and (2) the presence of only large granules ($> 1.2 \mu\text{m}$ diam.) in large granule hemocytes while small granule hemocytes may contain both large and small granules. Both types of granules were often surrounded by a clear (artifactual?) space (see Figs. 6B and C), and in *P. interruptus*, granules in the large granule hemocytes often did not section cleanly but appeared fractured (see Fig. 4C), unlike those present in small granule cells. The cytoplasm of granulocytes, both small and large granule hemocytes, contained



Figures 1–3. Light micrographs of hemocytes from *Panulirus interruptus* (Fig. 1), *Homarus americanus* (Fig. 2), and *Loxorhynchus grandis* (Fig. 3) showing hyaline cells (column A), small granule (column B), and large granule (column C) types. Note the small size of the hyaline cells compared to the granulocytes. The large granule cells are highly refractile and it is difficult to observe the nucleus. All figures at 2600 \times ; scale bar = 10 μ m.

Golgi bodies, RER, vesicles, mitochondria, ribosomes, and microfilaments scattered between the granules (see Fig. 7). Microtubules, typically in a band adjacent to the plasma membrane, were commonly seen.

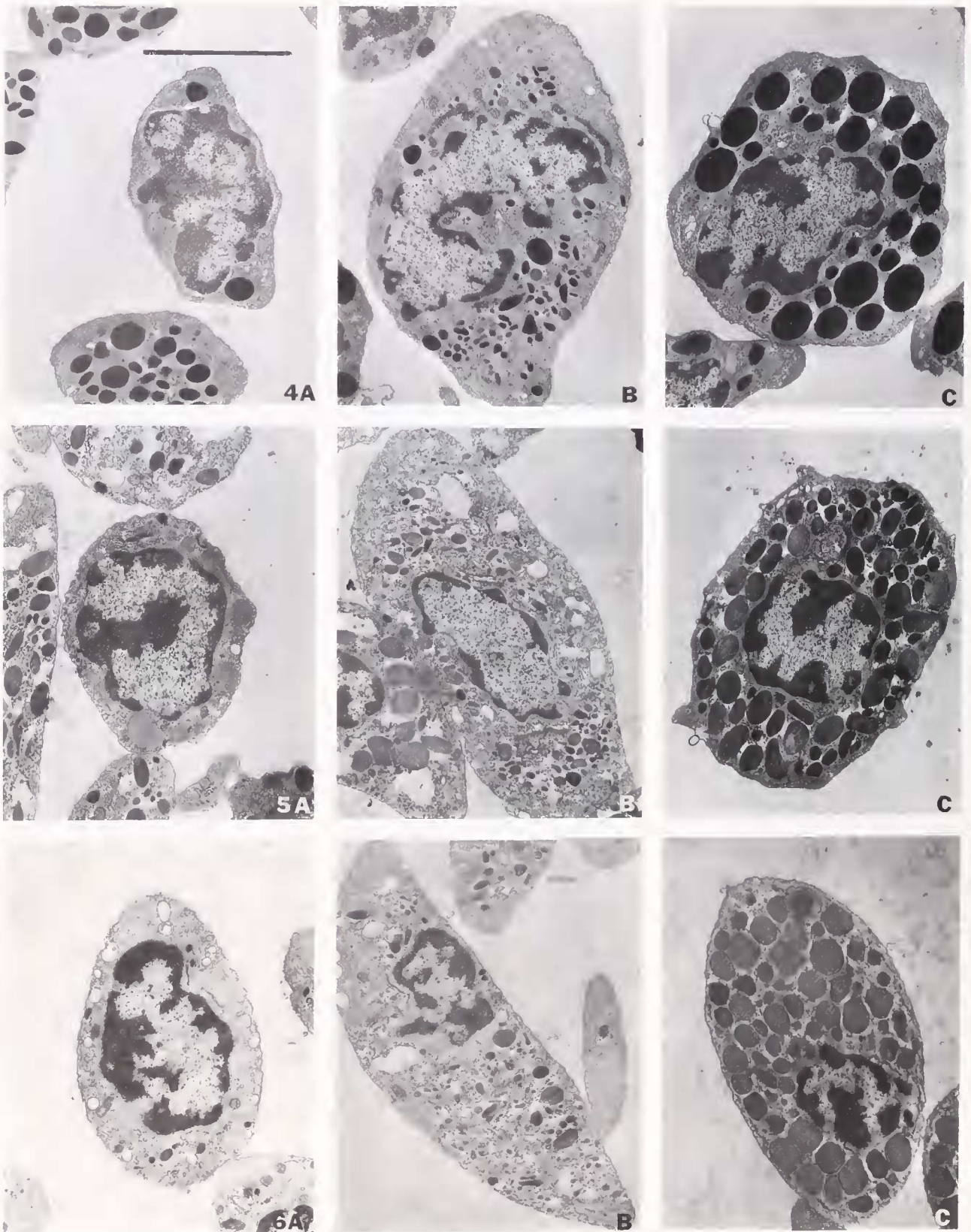
Hemocyte differential counts

Differential counts were performed using phase contrast LM and TEM (Table II). Although individual paired counts are similar, we consider the TEM counts more accurate for comparison because of the inherent greater resolution. *P. interruptus* had the highest percentage of hyaline cells at 56%, whereas *L. grandis* and *H. americanus* were considerably lower at 21% and 27%, respectively. Large granule granulocytes constituted be-

tween 10% and 13% of the total with small granulocytes comprising about 65% in *H. americanus* and *L. grandis* and 31% in *P. interruptus*.

Clotting

Patterns of coagulation. The species studied represent the three coagulation patterns described by Tait (1911). In *L. grandis* (Tait category A), the bulk of the clot consisted of long cellular aggregations linked by strands of clot material. The clot produced by *H. americanus* (Tait category B) contained isolated islands of coagulated hemolymph with intervening areas of packed hemocytes, whereas in *P. interruptus* (Tait category C), cell ag-



Figures 4-6. Transmission electron micrographs of hemocytes from *Panulirus interruptus* (Fig. 4), *Homarus americanus* (Fig. 5), and *Loxorhynchus grandis* (Fig. 6) showing hyaline (column A), small granule (column B) and large granule (column C) types. Granules are present in hyaline cells although not abundant. Small granule hemocytes are characterized by small granules in a relatively large amount of cytoplasm and in large granule hemocytes the granules fill much of the cytoplasm. All figures at 5500 \times ; scale bar = 5 μ m.

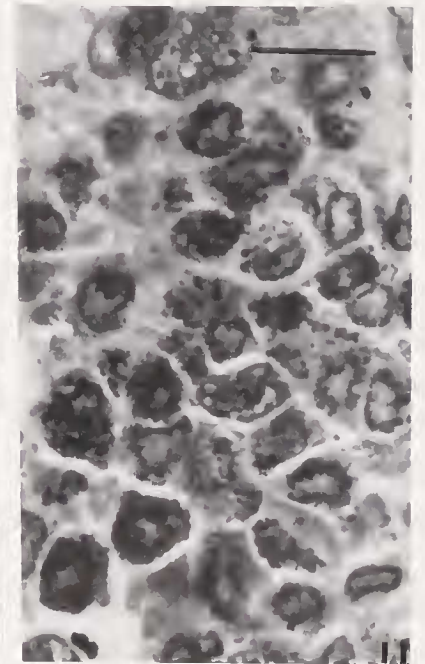
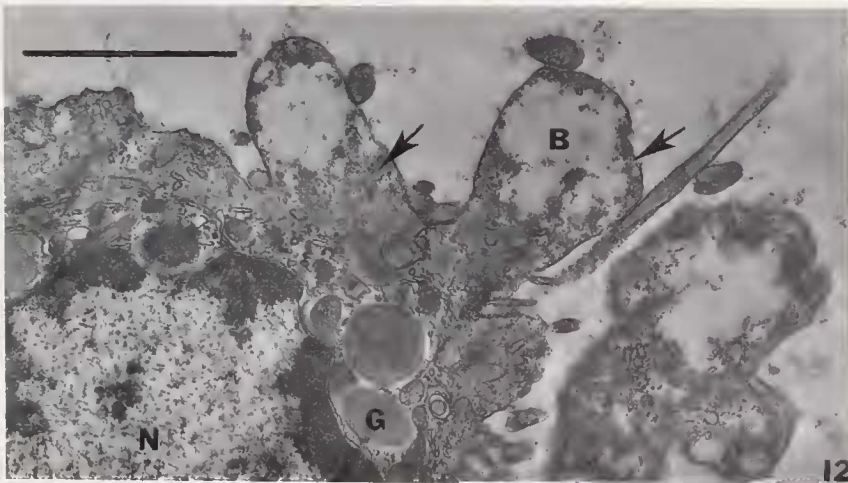
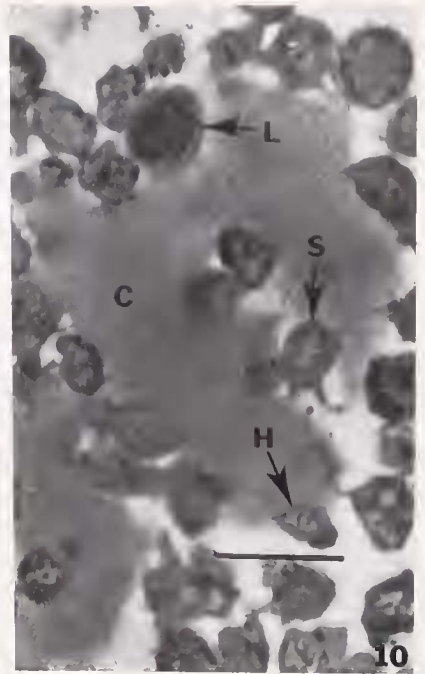
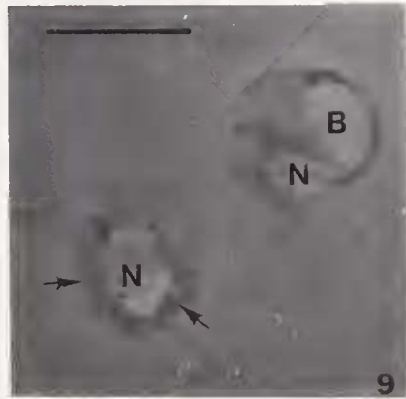
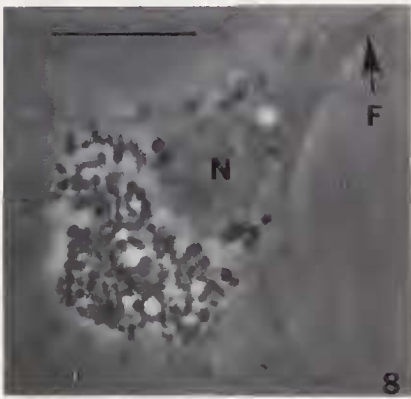


Figure 7. Transmission electron micrograph of a hyaline hemocyte from *Homarus americanus* showing cytoplasmic deposits (arrows). RER (R), a granule (G), vesicles (V), nucleus (N), and edge of Golgi body (GB). 70,000 \times ; scale bar = 0.5 μ m.

Figure 8. Light micrograph of a large granule hemocyte from *Panulirus interruptus* 2 min after mixing equal volumes of hemolymph and seawater containing trypan blue. Note the cell is intact and has spread on the glass substrate. Nucleus (N); filopodia (F). 2000 \times ; scale bar = 10 μ m.

Figure 9. Light micrograph of two hyaline cells from *P. interruptus* from the same preparation as cells in Figure 8. These cells have not attached to the substrate and they have lysed, leaving a light (blue-stained) nucleus (N), blebs (B), and thin rim of residual cytoplasm (arrows). 2000 \times ; scale bar = 10 μ m.

Figure 10. Light micrograph of hemocytes from *P. interruptus* during early clot formation (2 min after mixing with seawater). Note the clusters of hemocytes between the large circular areas of coagulated hemolymph (C). Large granule hemocytes (L); small granule hemocytes (S); and hyaline cell (H). 700 \times ; scale bar = 25 μ m.

Figure 11. Light micrograph of hemocytes from *Loxorhynchus grandis* during early clot formation (2 min after mixing with seawater). Note the large aggregation of hemocytes. Obvious areas of coagulated hemolymph are not present. 700 \times ; scale bar = 25 μ m.

Table II

Comparative hemocyte differential counts using light and transmission electron microscopy

	Large granule cells (%)	Small granule cells (%)	Hyaline cells (%)
<i>Homarus americanus</i>			
Light microscopy	16.4 ± 2.7 (10.0–26.5; 9)	60.2 ± 3.6 (41.5–76.2; 9)	22.4 ± 2.4 (11.9–34.2; 9)
Electron microscopy	10.3 ± 1.6 (7.8–19.5; 7)	62.4 ± 2.1 (53.8–71.3; 7)	27.3 ± 2.8 (15.2–35.9; 7)
<i>Panulirus interruptus</i>			
Light microscopy	9.8 ± 2.6 (4.0 + 21.0; 6)	29.2 ± 3.6 (22.0–45.5; 6)	61.0 ± 3.4 (50.0–72.0; 6)
Electron microscopy	12.6 ± 1.7 (6.3–18.7; 8)	31.1 ± 1.7 (26.6–40.2; 8)	56.3 ± 1.7 (48.5–62.8; 8)
<i>Loxorhynchus grandis</i>			
Light microscopy	14.1 ± 2.3 (6.0–21.0; 6)	67.8 ± 5.3 (49.0–79.0; 6)	18.1 ± 3.8 (11.0–35.0; 6)
Electron microscopy	10.4 ± 0.7 (8.0–13.0; 6)	68.8 ± 1.6 (62.2–72.0; 6)	20.8 ± 1.6 (15.4–25.6; 6)

Values are mean ± standard error (range; number of measurements).

gregates were small and widely separated by clotted hemolymph.

Trypan blue experiments. Previous work with decapods has shown hemocyte lysis to be the initiating step in hemolymph coagulation. The method used here to identify lysing hemocytes simulates coagulation resulting from a seawater influx such as a break in the exoskeleton. The addition of trypan blue (which does not alter the process of coagulation) facilitates early identification of lysing hemocytes. Cell categorization at the LM level is impossible following lysis; thus TEM was used to describe successive steps in coagulation (see next section). When hemolymph was mixed with seawater containing trypan blue, two populations of cells were observed. In one group, the cells contained distinct granules, spread on the glass slide, extended filopodia (Fig. 8), and did not accumulate trypan blue during the observation period. This group was composed of small and large granule hemocytes. The second group of cells remained ovoid and did not attach to or spread on glass slides; the cytoplasm and nucleus of these cells appeared blue. By 1 min, multiple blebs were apparent beneath the plasma membrane. Cytolysis occurred by 2 min in *L. grandis* and by 5 min

for the lobsters, leaving a blue-staining nucleus and fragments of cytoplasm (Fig. 9). Visual observations of individual cells confirmed that the lysing cells were hyaline cells in all three species (Table III). In addition, the percentage of lysing cells in each species corresponded to the percentage of hyaline cells obtained from differential counts. Using the trypan blue method, the smallest proportion of clotting cells was found in *L. grandis* (19%), with *H. americanus* intermediate (34%) and *P. interruptus* highest (50–70%). We suggest that the coagulation patterns reported by Tait (1911) are not three distinct categories but rather represent a continuum relating to the percentage of hyaline cells. Species with the highest hyaline cell percentage exhibit type C coagulation; lysis of these cells results in large expanses of coagulated hemolymph with small intervening clusters of granulocytes. As the percentage of hyaline cells decreases, so does the amount of coagulated hemolymph. Therefore, in animals with type A coagulation, like the crab, the predominant feature is the aggregated granulocytes which are, in fact, connected by strands of coagulated hemolymph.

The trypan blue method was particularly useful with the crab because the hyaline cells are not abundant, lyse faster than in the other species, and the granulocytes rapidly attach to one another to produce large aggregations. Thus lysed cells in unstained preparations were difficult to identify within the mass of cells (primarily granulocytes) that appear unaffected and intact.

Morphology of coagulation. When equal volumes of hemolymph and seawater were mixed, coagulation began immediately and produced a strong clot within a few minutes. Clots produced in *P. interruptus* were composed primarily of coagulated hemolymph with hemocytes scattered throughout the matrix (Fig. 10). In *H. americanus*, less coagulated hemolymph was present and tightly compacted clusters of granulocytes were conspicuous. In *L. grandis*, the bulk of the clot was produced by aggregated cells (Fig. 11) and only strands of coagulated hemolymph.

In all three species, changes in cell morphology occurred primarily in the hyaline cells. Early changes involving loss of plasma membrane integrity were identical to those observed in the preceding trypan blue experiments. Electron microscopy revealed that the centers of the hyaline cell blebs appeared empty and were surrounded by round, electron-dense deposits (Fig. 12). Granules in these cells, which were homogeneous in sectioned material and dispersed throughout the cytoplasm,

Figure 12. Transmission electron micrograph of a hyaline cell from *L. grandis* 2 min after mixing with seawater showing the formation of blebs (B). Note the homogeneous granules (G) aggregated around the nucleus (N) and the small electron-dense deposits (arrows) throughout the cytoplasm. 12,000×; scale bar = 2.5 μm.

Table III

Comparative hemocyte functions

	Large granule cells (% positive)	Small granule cells (% positive)	Hyaline cells (% positive)
<i>Homarus americanus</i>			
Clotting:			
% accumulate trypan blue	0.0	1.2	100.0
Phagocytosis:			
% phagocytic	39.3	93.1	0.0
% dead (+ bacteria)	9.3	11.5	83.0
% dead (- bacteria)	0.0	0.0	29.7
Encapsulation:			
% of adherent cells	63.3	21.2	0.0
<i>Panulirus interruptus</i>			
Clotting:			
% accumulate trypan blue	0.0	0.0	100.0
Phagocytosis:			
% phagocytic	32.0	83.1	0.0
% dead (+ bacteria)	0.0	16.2	31.6
% dead (- bacteria)	0.0	0.0	1.6
Encapsulation:			
% of adherent cells	68.4	25.3	6.3
<i>Loxorhynchus grandis</i>			
Clotting:			
% accumulate trypan blue	0.3	0.7	100.0
Phagocytosis:			
% phagocytic	70.0	95.9	0.0
% dead (+ bacteria)	4.8	6.1	95.0
% dead (- bacteria)	16.7	1.7	24.3
Encapsulation:			
% of adherent cells	67.2	28.7	4.1

Mean percentage of each category which accumulates trypan blue, is phagocytic, or initiates encapsulation by adhering to fungal hyphae. In the clotting experiments, ≥ 100 hemocytes in each category were evaluated from each of 5 animals. In the phagocytosis experiments, ≥ 100 hemocytes in each category were evaluated from a single animal. Percentages of dead hemocytes were compared in the presence (+) and absence (-) of bacteria. In the encapsulation experiments, ≥ 100 hemocytes in each category were evaluated from each of 5 animals.

became concentrated around the nuclear envelope. As the plasma membrane over the blebs ruptured, cytoplasm containing the deposits and disrupted organelles was released. Surrounding the degenerating hyaline cell, long strands were formed in the hemolymph, which apparently hydrated into typical clot material. Concurrently, granules developed a scalloped margin, their contents became grainy, and adjacent granules sometimes fused. Granules released their constituents either by exocytosis or lysis into the cytoplasm.

As hyaline cells of *P. interruptus* lysed, spheres of coagulated hemolymph developed around each cell (Fig. 10). The spheres expanded and fused with adjacent spheres to produce a continuous hemolymph clot with clusters of granulocytes scattered between roughly spherical areas of coagulated hemolymph. Hemolymph clots of *Homarus* contained fewer areas of coagulated hemolymph and larger intervening granulocyte clusters. In contrast, the clotted hemolymph of *L. grandis* was composed of masses of aggregated granulocytes (Fig. 11) often adhering to long strands of clot material. The granulocytes in

all three species did not lyse during the 1-h time period examined in this study, although they extended filopodia. Large and small granule hemocytes rarely displayed exocytosis of granules.

Phagocytosis of bacteria

Phagocytosis of the Gram-negative bacterium *Cytophaga* sp. was performed by most small granule hemocytes, some large granule hemocytes, and none of the hyaline hemocytes (Table III). The percentage of phagocytic small granule hemocytes ranged from 83% to 96%, whereas only 30% to 67% of the large granule cells were phagocytic. In contrast to incubation in seawater, where cytolysis of hyaline cells was observed, most hyaline cells and granulocytes remained viable when incubated in SCM (shrimp culture medium) for the 2-h duration of the phagocytosis experiments. However, enhanced autolysis was observed when hyaline cells and granulocytes were cultured in the presence of bacteria (Table III). Hyaline cells that did not lyse during the experiments did not

Table IV

Comparative hemocyte cytochemistry

	Large granule cells	Small granule cells	Hyaline cells
<i>Homarus americanus</i>			
Acid phosphatase	48.3 ± 8.5 (25.0–80.0)	23.6 ± 8.0 (6.7–59.5)	0.5 ± 0.5 (0.0–2.9)
Prophenoloxidase	86.6 ± 5.2 (71.4–100.0)	10.8 ± 1.3 (5.0–14.3)	0.0 ± 0.0 (0.0–0.0)
Sudan Black B	0.0 ± 0.0 (0.0–0.0)	0.4 ± 0.4 (0.0–2.5)	99.4 ± 0.6 (96.1–100.0)
<i>Panulirus interruptus</i>			
Acid phosphatase	72.1 ± 6.4 (44.4–90.0)	69.4 ± 7.2 (41.0–91.5)	4.9 ± 1.7 (0.0–11.1)
Prophenoloxidase	96.8 ± 3.4 (91.7–100.0)	35.2 ± 4.9 (20.7–55.7)	0.2 ± 0.2 (0.0–1.0)
Sudan Black B	0.0 ± 0.0 (0.0)	0.0 ± 0.0 (0.0)	99.6 ± 0.2 (98.8–100.0)
<i>Loxorhynchus grandis</i>			
Acid phosphatase	88.7 ± 5.8 (61.5–100.0)	76.6 ± 7.7 (51.9–96.5)	11.4 ± 2.8 (1.9–22.6)
Prophenoloxidase	100.0 ± 0.0 (100.0)	53.4 ± 4.2 (41.8–66.7)	1.0 ± 1.0 (0.0–5.9)
Sudan Black B	0.0 ± 0.0 (0.0)	0.4 ± 0.2 (0.0–1.3)	100.0 ± 0.0 (100.0)

Percentage of positive hemocytes ± standard error. Minimum and maximum values are in parenthesis. Twenty large granule, 50 small granule, and 50 hyaline hemocytes were examined from each of 6 animals.

attach to the glass and spread as did the granulocytes, but often adhered to the granulocytes and remained ovoid. Total phagocytosis rates (defined as the number of phagocytic cells divided by the total number of surviving hemocytes) were 79% and 88%, respectively, for *H. americanus* and *L. grandis* (the two species with no survival of hyaline hemocytes) and 54% for *P. interruptus* which had higher hyaline cell survival.

Encapsulation of fungal hyphae

LM observations of initial hemocyte contact with fungal hyphae showed that approximately two-thirds of adherent cells were large granule hemocytes, between 20% and 30% were small granule hemocytes and only small percentages were hyaline hemocytes (Table III). For all three species, percentages of adherent large granule cells were enriched 7 to 15 times over those found in hemolymph.

Hemocyte cytochemistry

Hemocyte smears were stained to identify sites of lipid (with Sudan black B), or acid phosphatase, or PPO activity (Table IV). Sudan black B, which stains lipids and

lipoproteins, produced diffuse cytoplasmic staining in all hyaline cells of each species. However, the staining intensity was less than that previously reported for deposit-containing hyaline cells of the penaeid shrimp in which the entire cytoplasm is darkly stained in a clumpy pattern (Hose *et al.*, 1987). In the present species, the light grey, homogeneous staining of the cytoplasm was difficult to detect without prior experience with the stain. The most distinctive feature in Sudan black-stained cells was that the nucleus in hyaline cells was obscured by the stain, similar to that observed in the shrimp (Hose *et al.*, 1987). Granules in the hyaline cells of all three species did not accumulate the stain, although membranes around the larger granules in some hyaline hemocytes of *H. americanus* displayed intense staining. The cytoplasm of the granulocytes remained unstained by Sudan black B and the nucleus was always visible. Except for intense staining of granule membranes in large granule hemocytes of *H. americanus*, staining reactions of granulocytes were identical to those reported for shrimp hemocytes.

Reaction sites demonstrating acid phosphatase were rare in hyaline cells and more abundant in granulocytes (Table IV). For each species, ranges of the percentages of positive cells did not overlap between the two categories. Most small granule hemocytes had few to an intermediate number of foci. As observed in the shrimp (Hose *et al.*, 1987), not all large granule hemocytes contained reaction sites, but positive cells had numerous foci. In *L. grandis*, acid phosphatase was primarily located in the granules, although some vesicles and tubules (most likely RER) stained positive as well. In the lobsters, only a few granules contained acid phosphatase and most of the reaction sites were located in vesicles and tubules of RER.

PPO activity was restricted to granulocytes (only one out of approximately 300 hyaline hemocytes of the crab and spiny lobster appeared positive). From 11% (*H. americanus*) to 53% (*L. grandis*) of small granule hemocytes had positively stained granules, whereas most (>87%) large granule hemocytes contained numerous dark-staining granules. The cytoplasm of large granule cells also contained PPO while staining in small granule hemocytes was confined to the granules.

Discussion

Our results suggest that hemocytes of decapod crustaceans are composed of two major groups, hyaline cells and granulocytes, which have distinct functional and cytochemical differences. Most investigators have historically recognized these two categories and separated them using morphological criteria (see Martin and Graves, 1985, for review). However, our work demonstrates that the morphological features traditionally used to identify these categories do not reliably correlate with cellular

functions. Although granulocytes of the three species studied in this paper, the penaeid shrimp (*Sicyonia ingentis*) used to develop the system, and several other species described in the literature (Bauchau, 1981) are morphologically almost indistinguishable, hyaline hemocytes constitute a heterogeneous group. Our observations may explain much of the confusion in the literature regarding hemocyte morphology and function. Such discrepancies have prevented information obtained on a particular species to be readily interpreted with regard to other decapods. In some cases, functional studies have not identified cell types involved in hemolymph coagulation and phagocytosis. For example, both Schapiro *et al.* (1977) and Goldenberg *et al.* (1986) presented quantitative data on phagocytosis of bacteria by *H. americanus* hemocytes, but neither group could identify the phagocytic hemocytes. In other cases, morphological identification did not correspond to functional roles. For instance, Söderhäll *et al.* (1986) refer to the hyaline cell as the main phagocytic hemocyte in the crab *Carcinus maenas* whereas in the crayfish *Pacifastacus leniusculus* phagocytosis is performed by both hyaline cells and semigranular cells. Such lack of consistency in ascribing similar functions to apparently similar hemocyte types stems from difficulties of using a classification system based on traditional morphological interpretations of hyaline and granular hemocytes (*i.e.*, granule number and size). Our data show that, for the four species investigated thus far, function is correlated with other morphological features such as cell size, nucleocytoplasmic ratio, and the presence of cytoplasmic deposits.

Historically, a second area of confusion is the identity of the type of hemocyte that initiates coagulation. Responsible cells have been described as either "explosive corpuscles" and "hyaline cells" (Wood and Visentin, 1967; Wood *et al.*, 1971; Ravindranath, 1980) or granulocytes (Toney, 1958; Hearing and Vernick, 1967; Mengeot *et al.*, 1977; Madaras *et al.*, 1981). Our studies provide an answer for the apparent confusion regarding the identity of clotting hemocytes. Hyaline cells lyse and initiate coagulation in all species; however in different species, these cells exhibit variations in the abundance and size of granules. For example, the granules of *Loxorhynchus grandis* are so abundant that the hyaline cells are easily confused with granulocytes while in *Panulirus interruptus*, the granules in large granule and hyaline hemocytes are approximately the same size. Hyaline hemocytes do have in common numerous, 50-nm diameter cytoplasmic deposits. These deposits can be detected using TEM, a technique rarely included in previous classification schemes, and by their propensity to stain with Sudan Black B.

We avoided the use of the term "hyaline cell" in our previous publications (Martin and Graves, 1985; Martin *et al.*, 1987; Hose *et al.*, 1987; Hose and Martin, 1989;

Omori *et al.*, 1989) in an attempt to avoid bias in developing a classification scheme and instead referred to deposit cells (with and without granules), small granule and large granule hemocytes. We now consider that shrimp deposit cells are equivalent to hyaline cells. Therefore, in an attempt to simplify the classification of crustacean hemocytes, we suggest the following categories of hemocytes: hyaline, small and large granule hemocytes. It is very important to recognize that morphology alone is insufficient for assigning any cell to one of these categories; instead the following criteria for hemocyte identification are suggested.

Hyaline cells have a nucleocytoplasmic ratios of >0.35 and lyse during clot formation. Because lysis is rapid, identification of these cells, especially in species with relatively low numbers of hyaline cells, is facilitated by mixing a trypan blue-seawater solution with hemolymph. Hyaline cells turn blue prior to lysis, thereby allowing morphological identification of the cell and observation of changes in cell morphology during coagulation. At the TEM level, these cells contain tiny cytoplasmic deposits that appear to be involved with the clotting process because they are only present in the hyaline cells and their release from the lysing cell precedes hemolymph coagulation. In addition, hyaline cells in the species we have studied (this paper and Hose *et al.*, 1987), selectively stain with Sudan Black B. Although this is a general stain for lipid, it has also been shown to stain coagulogen isolated electrophoretically (Durliat, 1985). Coagulogen may be contained within hyaline hemocytes or perhaps produced but not stored in high levels by these hemocytes. In crustacean hyaline cells, the cytoplasmic deposits are sudanophilic, with the most intense staining observed from the clustered deposits present in shrimp (Hose *et al.*, 1987). Although the test is useful, interspecific variations in the intensity of Sudan Black B staining are subtle and require careful interpretation. The less subjective criterion for a positive reaction is the obscurity of the nucleus by the stain.

Our results suggest that coagulation in decapods involves a common mechanism; the release of cytoplasmic material through breaks in the plasma membrane, possibly including the granules. The identity of the materials released is not clear. It has been suggested that (1) coagulogen, the clotting protein, is found in the plasma and activated by chemicals released from hemocytes and (2) coagulogen and its activators are released from cells (see Omori *et al.*, 1989). Ghidalia *et al.* (1981) reviewed this topic and demonstrated the presence of coagulogen in the plasma of decapods representing Tait's (1911) three patterns of coagulation. Although the presence of coagulogen in plasma could result from lysis of hyaline hemocytes during cell separation, these investigators used an anticoagulant (1:9, hemolymph:10% sodium citrate, v:v) which we have shown to be effective in preventing hya-

line cell lysis. They conclude that differences between the three coagulation patterns are probably due to the manner in which the clot-initiating materials are released. From the present study we show that decapods placed in Tait's category C (characterized by rapid gelation of the plasma) have twice the percentage of hyaline cells as in species where hemocyte aggregation occurs followed by slight gelation of the plasma (Tait's category A). What remains unclear is the localization of the clotting protein coagulogen (in cells, plasma, or both) and an identification of the material released from the hyaline cells that initiates coagulation. The most abundant cytoplasmic material released during coagulation is the electron-dense deposits. These deposits were identified in the hyaline cells of all decapods we examined using TEM and appear similar to published micrographs of coagulocytes in some insects (Ratcliffe and Rowley, 1979). Clearly a specific labelling technique for these deposits and coagulogen is needed, as in Bohn *et al.*'s (1981) immunocytochemical study of insect coagulogen.

Granulocytes, the second major category of decapod hemocytes, have a nucleocytoplasmic ratio of <0.35 and they do not accumulate trypan blue or lyse rapidly in culture. They are identified by the presence of numerous cytoplasmic granules, positive staining reactions for acid phosphatase and PPO, and *in vitro* phagocytosis of bacteria and attachment to fungal hyphae. The two subdivisions of granulocytes may be distinguished by (1) central location of nuclei in small granule hemocytes and eccentric location of nuclei in large granule hemocytes, (2) the presence of only large granules in large granule hemocytes whereas in small granule hemocytes there is a mixture of granules with varying sizes, and (3) the refractile nature of granules only in large granule hemocytes when examined by phase contrast microscopy.

The functional roles of granulocytes correlate well with observed cytochemical features. Granulocytes are the primary defensive cells of the hemolymph and the two subtypes perform overlapping functions. Small granule hemocytes are the main cells involved in phagocytosis and contain many lysosomes, while large granule cells, which most frequently initiate encapsulation of fungi, show more intense staining for PPO (Hose and Martin, 1989).

The functional and cytochemical criteria for recognizing two categories of hemocytes (hyaline cells and granulocytes) are further supported by observations of hemocyte maturation within the hematopoietic tissue of the shrimp (Martin *et al.*, 1987). In this species, we observed mitosis only in agranular hyaline cells and small granule hemocytes. Clusters of hyaline cells and granulocytes were segregated within the hematopoietic tissue (Martin *et al.*, 1987). We propose that the two hemocyte categories represent two cell lines. Cell size is significantly smaller in hyaline cells and is discontinuous between hy-

aline cells and small granule hemocytes. The nucleocytoplasmic ratios of hyaline cells of shrimp and the three species considered here are significantly higher than those of granulocytes. The ratios of two granulocyte categories overlap and decrease in large granule hemocytes coincident with increases in granule number and size (Table I). Granulocytes thus appear as a continuum of differentiation from the less mature small granule hemocytes to the large granule hemocytes.

To summarize, a combination of morphological, cytochemical and functional methods must be used to identify decapod hemocytes, because traditional morphological features are inadequate and misleading, especially with regard to hyaline cells. Further studies by investigators utilizing other decapods are necessary to test the usefulness of this classification scheme and to offer improvements by developing more specific criteria.

Acknowledgments

We want to thank Heidi Parker and Laura Targart for collecting and maintaining the crustaceans; Sidne Omori, Cathy Corazine, Celeste Chong, and Erin Campbell for technical support; and Dr. Don Lightner and Leona Mohny for supplying the cultures of *Fusarium solani*. The project was supported by NSF grant DCB-8502150 to GM and JEH.

Literature Cited

- Bauchau, A. G. 1981. Crustaceans. Pp 386-420 in *Invertebrate Blood Cells*, Vol. 2. Academic Press, New York.
- Bohn, H., B. Barwig, and B. Bohn. 1981. Immunochemical analysis of hemolymph clotting in the insect *Leucophaea medaruae* (Blattaria). *J. Comp. Physiol.* **143B**: 169-184.
- Brody, M., and E. Chang. (In press). Ecdysteroid effects on primary cell cultures. *Int. J. Invertebr. Repro. Dev.*
- Cornick, J. W., and J. E. Stewart. 1978. Lobster (*Homarus americanus*) hemocytes: classification, differential counts and associated agglutinin activity. *J. Invertebr. Pathol.* **31**: 194-203.
- Durliat, M. 1985. Clotting processes in Crustacea Decapoda. *Biol. Rev.* **60**: 473-498.
- Ghidalia, W., R. Vendrely, C. Montmory, Y. Coirault, and M. O. Brouard. 1981. Coagulation in decapod crustacea. *J. Comp. Physiol.* **142**: 473-478.
- Goldenberg, P. Z., A. H. Greenberg, and J. M. Gerrard. 1986. Activation of lobster hemocytes: cytoarchitectural aspects. *J. Invertebr. Pathol.* **47**: 143-154.
- Hearing, V. J., and S. H. Vernick. 1967. Fine structure of the blood cells of the lobster, *Homarus americanus*. *Ches. Sci.* **8**: 170-186.
- Hose, J. E., G. G. Martin, V. A. Nguyen, J. Lucas, and T. Rosenstein. 1987. Cytochemical features of shrimp hemocytes. *Biol. Bull.* **173**: 178-187.
- Hose, J. E., and G. G. Martin. 1989. Defense functions of granulocytes in the ridgeback prawn *Sicyonia ingentis* Burkenroad 1938. *J. Invertebr. Pathol.* **53**: 335-346.
- Madaras, F., M. Y. Chew, and J. D. Parkin. 1981. Purification and characterization of the sand crab (*Ovalipes bipustulatus*) coagulogen (fibrinogen). *Thromb. Haemost.* **45**: 77-81.
- Martin, G. G., and B. L. Graves. 1985. Fine structure and classification of shrimp hemocytes. *J. Morphol.* **185**: 339-348.

- Martin, G. G., J. E. Hose, and J. J. Kim. 1987. Structure of hemato-poietic nodules in the ridgeback prawn *Sicyonia ingentis*: light and electron microscopic observations. *J. Morphol.* **192**: 193–204.
- Mengeot, J. C., A. G. Bauchau, M. B. DeBrouwer, and E. Passelecq-Gérin. 1977. Isolément des granules des hémocytes de *Homarus vulgaris*. Examens électrophorétiques du contenu protéique des granules. *Comp. Biochem. Physiol.* **58(A)**: 393–403.
- Omori, S. A., G. G. Martin, and J. E. Hose. 1989. Morphology of hemocyte lysis and clotting in the ridgeback prawn, *Sicyonia ingentis*. *Cell Tissue Res.* **255**: 117–123.
- Ratcliffe, N. A., and A. F. Rowley. 1979. Role of hemocytes in defense against biological agents. Pp 332–414 in *Insect Hemocytes: Development, Form, Functions and Techniques*, A. P. Gupta, ed. Cambridge University Press, Cambridge.
- Ratner, S., and S. B. Vinson. 1983. Phagocytosis and encapsulation: cellular immune responses in Arthropoda. *Am. Zool.* **23**: 185–194.
- Ravindranath, M. H. 1980. Haemocytes in haemolymph coagulation of arthropods. *Biol. Rev.* **55**: 139–170.
- Shapiru, H. C., J. F. Steenbergen, and Z. A. Fitzgerald. 1977. Hemocytes and phagocytosis in the american lobster, *Homarus americanus*. Pp 126–134 in *Comparative Pathology*, Vol. 3. Plenum Press, New York.
- Söderhäll, K. 1982. Prophenoloxidase activating system and melanization—a recognition mechanism of arthropods? A review. *Dev. Comp. Immunol.* **6**: 601–611.
- Söderhäll, K., V. J. Smith, and M. W. Johansson. 1986. Exocytosis and uptake of bacteria by isolated haemocyte populations of two crustaceans evidence for cellular co-operation in the defense reactions of arthropods. *Cell Tissue Res.* **245**: 43–49.
- Spurrs, A. 1969. A low viscosity epoxy embedding medium for electron microscopy. *J. Ultrastruct. Res.* **26**: 31–43.
- Tait, J. 1911. Types of crustacean blood coagulation. *J. Mar. Biol. Assoc. U. K.* **9**: 191–198.
- Toney, M. E. 1958. Morphology of the blood cells of some crustacea. *Growth* **22**: 35–50.
- Wood, P. J., and L. P. Visentin. 1967. Histological and histochemical observations of the hemolymph cells in the crayfish, *Orconectes virilis*. *J. Morphol.* **123**: 559–568.
- Wood, P. J., J. Podlewski, and T. E. Shenk. 1971. Cytochemical observations of hemolymph cells during coagulation in the crayfish, *Orconectes virilis*. *J. Morphol.* **134**: 479–488.